RESEARCH ARTICLE
doi: 10.2306/scienceasia1513-1874.2026.097

ScienceAsia 52 (5): 2026: ID 2026097: **1–8**

Moringa oleifera seeds attenuate thyroid inflammation and autoimmune responses in a mouse model of Hashimoto's thyroiditis

Yuchen Yuan, Nian Liu, Diwen Wang, Chengsong Ye, Lulu Zhou, Delu Zheng*

Department of Endocrinology, The Second Affiliated Hospital of Bengbu Medical University, Bengbu, Anhui 233000 China

*Corresponding author, e-mail: 022019064@bbmu.edu.cn

Received 31 May 2026, Accepted 29 Sep 2026
Available online 12 Nov 2026

ABSTRACT: Hashimoto's thyroiditis (HT) is a chronic autoimmune disease characterized by lymphocytic infiltration and progressive destruction of thyroid follicles. Moringa oleifera seeds possess immunomodulatory and anti-inflammatory activities, yet their therapeutic potential in HT remains unclear. In this study, we used a mouse model of HT immunized with thyroglobulin (Tg) and an adjuvant. The mice were fed diets containing 2%, 5%, and 10% *M. oleifera* seeds for four weeks. Histopathological studies revealed that the thyroid glands of untreated HT mice exhibited degenerative changes and infiltration by inflammatory cells, whereas administration of *M. oleifera* seeds improved follicular structure and reduced inflammatory cell infiltration. Circulating autoantibodies—thyroid peroxidase antibody (TPOAb) and thyroglobulin antibody (TGAb)—were significantly elevated in HT controls but decreased in a dose-dependent manner with *M. oleifera* seeds. Furthermore, the HT model exhibited increased pro-inflammatory markers (IFN-γ, TNF-α, IL-6, IL-1β, and IL-17) and decreased anti-inflammatory IL-10 levels in both blood and thyroid tissue. Treatment with *M. oleifera* seeds significantly ameliorated this immunological imbalance by modulating inflammatory markers and enhancing IL-10 production. These findings provide novel evidence supporting the potential use of *M. oleifera* seeds as a therapeutic agent for thyroiditis—restoring cytokine balance and alleviating autoimmune-mediated thyroid injury—suggesting their utility as a nutraceutical immunomodulator for HT.

KEYWORDS: *Moringa oleifera* seeds, Hashimoto's thyroiditis, inflammatory cytokines, thyroid tissue

INTRODUCTION

HT is a chronic autoimmune disorder characterized by destruction of thyroid tissue, marked lymphocytic infiltration, and persistently elevated serum levels of TPOAb and TGAb [1, 2]. HT is the most common cause of hypothyroidism in regions with adequate dietary iodine intake. The etiology involves an interplay among multiple genetic factors, environmental triggers, and immunological dysfunction [3, 4]. Treatment options include, but are not limited to, levothyroxine (L-thyroxine), corticosteroid therapy, selenium supplementation, vitamin D supplementation, and surgical intervention [2, 5]. However, each of these interventions has limitations, suggesting a need for more targeted therapies addressing the underlying autoimmune pathogenesis of HT. Inflammatory cytokines play a critical role in the onset and progression of HT. Numerous pro-inflammatory cytokines are implicated in the inflammatory process associated with HT. Both HT patients and experimental animal models consistently exhibit upregulation of cytokines and other inflammation-associated mediators—such as IFN-γ, TNF-α, IL-6, IL-1β, and IL-17—which are significantly elevated [6, 7]. These molecules induce apoptosis of thyroid follicular epithelial cells, recruit inflammatory cells to infiltrate the thyroid gland, and sustain active autoimmunity [1]. On the other hand, IL-10, which is a powerful anti-inflammatory cytokine, is often downregulated in HT [8]. The reduced production of this cytokine impairs the regulation of excessive immune responses, leading to chronic inflammation and subsequent tissue damage. Therefore, an imbalance of pro-inflammatory and anti-inflammatory cytokines may play an important role in the pathogenesis of HT.

Currently, researchers have shown keen interest in exploring the roles of naturally occurring bioactive compounds and food-derived immunoregulatory agents in modulating autoimmunity [9, 10]. *M. oleifera* seeds are widely recognized as an alternative medicine or functional food because they contain numerous bioactive compounds. They are rich in several phytochemicals, including glucosinolates, flavonoids, phenolic acids, and omega-3 fatty acids. All of these compounds exhibit proven anti-inflammatory, antioxidant, and immunomodulatory activities [11, 12]. It has been previously demonstrated3 that *M. oleifera* seeds inhibit the production of pro-inflammatory cytokines and chemokines, in part through inhibition of nuclear factor kappa-B (NF-κB) signaling, while simultaneously increasing the production of anti-inflammatory cytokines—such as IL-10—that help restore immune homeostasis [12, 13]. Although the link between inflammation and immune-mediated diseases is well established, its role in autoimmune thyroid disease—particularly HT—has not yet been thoroughly investigated. Therefore, after detailed analysis of thyroid

pathology, measurement of thyroid-specific autoantibodies, and assessment of inflammatory mediators, we sought to determine whether *M. oleifera* seed treatment alleviates autoimmune thyroid inflammation and restores immune homeostasis. The results of this study may provide novel scientific evidence supporting the use of *M. oleifera* seeds as a natural and safe nutritional intervention for HT.

MATERIALS AND METHODS

Animals

Healthy female non-obese diabetic (NOD) mice (9 weeks old, weighing 20 ± 2 g) were obtained from Changzhou Cavins Laboratory Animal Co., Ltd., Changzhou, Jiangsu, China. The mice were maintained under controlled environmental conditions with a 12-hour light/12-hour dark cycle at a temperature of 22 ± 1 °C and relative humidity of 45–55%. They had ad libitum access to standard chow and drinking water and were acclimatized for one week prior to experimentation. At the end of the study, anesthesia was induced in mice with 3% isoflurane (administered in a dedicated induction chamber) and maintained with 1.5% isoflurane via a nose cone. Blood samples (0.5–0.8 ml) were collected via abdominal aortic puncture under deep anesthesia. After blood collection, the animals were euthanized by exsanguination under deep anesthesia, and death was confirmed by permanent cessation of heartbeat and spontaneous respiration. No animal exhibited signs of recovery during or after the procedure. In accordance with the Guide for the Care and Use of Laboratory Animals, all animal experimental procedures were approved by the Animal Research Ethics Committee of the Second Affiliated Hospital of Bengbu Medical University (Approval No. Lundongke-2024-404).

Animal model and treatment

The model group mice were subcutaneously injected with 100 µl of Freund's complete adjuvant (CFA; Cat. No. F5881, Sigma-Aldrich, St. Louis, MO, USA), emulsified with 25 µg of porcine thyroglobulin (Tg; Cat. No. T1126, Sigma-Aldrich) at the base of the tail. Fourteen days later, they received a second subcutaneous injection of 100 µl of Freund's incomplete adjuvant (IFA; Cat. No. F5506, Sigma-Aldrich), also emulsified with 25 µg of Tg, at the same site. During this period, the mice were provided with standard rodent chow. The control group mice received phosphate-buffered saline (PBS; Cat. No. BL316A, Beijing Lanjieke Technology Co., Ltd., Beijing, China) instead of Tg and underwent injections at identical time intervals while maintained on standard rodent chow. Mice were randomly assigned to experimental groups ($n = 7$ per group). Following completion of the immunization protocol, mice in the *M. oleifera* seed—treatment groups were switched to diets supplemented with 2%, 5%, or 10% (w/w) ground *M. oleifera* seed powder for four weeks. The control and untreated model groups continued to receive standard rodent chow during the same four-week period. *M. oleifera* seeds were purchased from a commercial supplier in Bozhou, Anhui Province, China—a major hub for traditional Chinese medicinal materials. The seeds originated from Yunnan Province, China and were certified as food-grade cultivated products (expiry date: 2025-07-25). Prior to diet preparation, the seeds were ground into fine powder and thoroughly homogenized with standard rodent chow. At the end of the feeding regimen, mice from all groups were euthanized to collect serum and thyroid tissue for subsequent analyses [14–17].

Hematoxylin and eosin (H&E) staining

Thyroid tissues were immersed in 4% paraformaldehyde solution (Cat. No. P1110, Solarbio, Beijing, China) and fixed overnight at room temperature. Following fixation, the tissues were dehydrated through a graded ethanol series and embedded in paraffin. Paraffin blocks were sectioned into 4-µm-thick slices using a microtome (Model RM2235, Leica, Germany). The sections were stained with hematoxylin and eosin (H&E) using hematoxylin solution (Cat. No. H8070, Solarbio) and eosin solution (Cat. No. A600190, Sangon Biotech, Shanghai, China). After staining, the slides were mounted with neutral balsam (Cat. No. Q/YSQN 41-91, Shanghai Specimen Model Factory, Shanghai, China) and air-dried. Images were acquired using a digital trinocular microscope imaging system (Model DP73, Olympus).

Enzyme-linked immunosorbent assay (ELISA)

Serum concentrations of TPOAb and TGAb in mice were quantified using ELISA kits (EM1419 and EM1402, respectively; Fei En Biotech, Wuhan, Hubei, China). The levels of IL-6, IL-10, IFN-γ, IL-17, and TNF-α in mouse serum samples were measured using the following ELISA kits: WLE04, WLE03, WLE07, WLE1946, and WLE05 (Fei En Biotech), respectively.

Reverse transcription quantitative PCR (RT-qPCR)

Total RNA was extracted from thyroid tissues using TRIzol reagent (Cat. No. RP101, YoungGen, Kunming, Yunnan, China) according to the manufacturer's instructions. RNA concentration and purity were assessed using a spectrophotometer (NanoDrop 2000, Thermo Fisher Scientific, Waltham, MA, USA), and samples with A260/A280 ratios between 1.8 and 2.0 were considered high quality. First-strand cDNA was synthesized from 1 µg of total RNA using the HP All-in-One qRT Master Mix (Cat. No. RT203, YoungGen) following the manufacturer's protocol.

Quantitative PCR was performed using $2 \times$ SYBR Green PCR Master Mix (Cat. No. SR4110, Solarbio) on a Pangaea 3 Real-Time PCR System (Pangaea Biotechnology, Beijing, China). The PCR cycling conditions

were as follows: initial denaturation at 95 °C for 5 min, followed by 40 cycles of denaturation at 95 °C for 10 s, annealing at 60 °C for 10 s, and extension at 72 °C for 15 s. Melting curve analysis (60–94 °C, at a heating rate of 0.5 °C/s) was performed after the final cycle to verify amplification specificity.

Gene expression levels were quantified using the $2^{-\Delta\Delta C_T}$ method, with β-actin serving as the internal reference gene. All reactions were performed in technical triplicate, and data are presented as relative fold change normalized to the control group. Primer sequences are listed in Table S1 [18].

Lymphocyte infiltration assessed by CD3 and CD19 immunohistochemistry

Thyroid tissue sections (5 µm) were deparaffinized and rehydrated using standard protocols. Antigen retrieval was performed in citrate buffer (pH 6.0) by microwave heating for 10 min. Endogenous peroxidase activity was quenched with 3% H_2O_2 for 15 min, and nonspecific binding was blocked with 1% BSA in PBS for 15 min. Sections were incubated overnight at 4 °C with primary antibodies against CD3 (Cat. No. DF6594, Affinity Biosciences, Changzhou, Jiangsu, China) and CD19 (Cat. No. DF7030, Affinity Biosciences), both diluted 1:100 in PBS. After washing, HRP-conjugated goat anti-rabbit IgG secondary antibody (Cat. No. 31460, Thermo Fisher Scientific) was applied at a dilution of 1:500 for 60 min at 37 °C. Signals were visualized using a DAB substrate kit (Cat. No. DAB-1030, Maxim Biotech, Fuzhou, Fujian, China), and nuclei were counterstained with hematoxylin. Stained sections were dehydrated, cleared, and mounted. Images were acquired using an Olympus BX53 microscope. For quantitative analysis, five random nonoverlapping fields per section at 400 × magnification were captured, and the mean optical density of CD3- and CD19-positive signals was measured using ImageJ software after background subtraction.

Statistical analysis

All statistical and correlation analyses were performed using SPSS version 29.0 (IBM Corp., Armonk, NY, USA). Data are presented as the mean ± standard deviation (SD). Differences among multiple groups were analyzed with one-way ANOVA followed by Dunnett's post hoc test, applying Bonferroni adjustment where appropriate. A p-value of less than 0.05 was considered statistically significant.

RESULTS

M. oleifera seeds alleviated thyroid dysfunction in HT mice

Immunization with thyroglobulin in adjuvant emulsion successfully induced the HT mouse model. Representative microscopic images are shown in Fig. 1. In the control group, thyroid follicles were structurally intact and regularly arranged, with minimal inflammatory cell infiltration. In contrast, the HT model group exhibited severe follicular atrophy, destruction of follicular architecture, and extensive inflammatory cell infiltration in thyroid tissue. After treatment with graded doses of *M. oleifera* seed powder, thyroid histological injury was effectively ameliorated in a dose-dependent manner. Medium- and high-dose *M. oleifera* seed powder notably restored follicular morphology and reduced inflammatory infiltration, indicating that *M. oleifera* seed powder alleviated thyroid tissue damage caused by autoimmune thyroiditis (Fig. 1).

M. oleifera seeds reduced serum TPOAb and TGAb levels in HT mice

To investigate whether *M. oleifera* seed powder modulates thyroid autoantibody production in HT mice, serum concentrations of TPOAb and TGAb were quantified by ELISA. Consistent with previous reports, HT mice exhibited markedly elevated serum TPOAb and TGAb titers, characteristic of autoimmune thyroid injury. Dietary supplementation with graded doses (2%, 5%, and 10% w/w) of *M. oleifera* seed powder reduced circulating levels of both autoantibodies in a dose-dependent manner. Significant differences were observed between the HT model group and each treatment group (** $p < 0.01$, *** $p < 0.001$, **** $p < 0.0001$; Fig. 2). Collectively, these serological results indicate that *M. oleifera* seed powder alleviates thyroid autoimmunity in HT mice by suppressing thyroid-specific autoantibody production.

M. oleifera seeds modulated inflammatory factors in HT mice

To characterize how *M. oleifera* seed powder modulates systemic and local thyroid inflammation in HT mice, we quantified key inflammatory cytokines at both the serum protein and thyroid tissue transcriptional levels.

Serum ELISA analysis (Fig. 3) revealed a disordered cytokine profile in the untreated HT model group, characterized by elevated pro-inflammatory cytokines (IFN-γ, TNF-α, IL-17, IL-6, and IL-1β) and reduced levels of the anti-inflammatory cytokine IL-10. Dietary supplementation with graded doses of *M. oleifera* seed powder corrected this inflammatory imbalance in a dose-dependent manner. The 10% seed powder treatment group exhibited the strongest anti-inflammatory effect: all detected pro-inflammatory cytokines were significantly lower than those in the HT model group (**** $p < 0.0001$), whereas IL-10 levels were markedly elevated compared with the untreated HT model group (**** $p < 0.0001$).

Thyroid tissue mRNA quantification by qPCR (Fig. 4) further confirmed transcriptional changes consistent with the serum ELISA results. The HT model group showed elevated mRNA expression of *Ifng*, *Tnf*, *Il17a*, *Il6*, and *Il1b*, accompanied by suppressed *Il10* transcription. Consistent with the serum protein data,

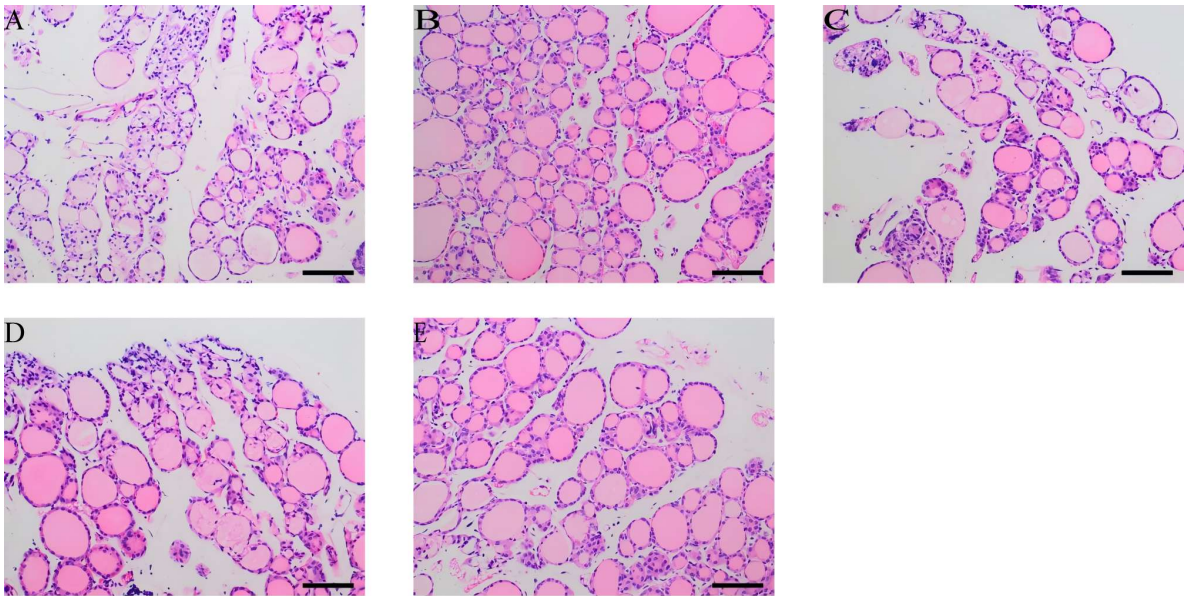

Fig. 1 Amelioration of thyroid pathology by *M. oleifera* seeds in HT mice. Representative H&E-stained images of thyroid tissue are shown. Scale bar = 50 µm. (A) Control group; (B) HT model group; (C) HT + 2% *M. oleifera* seeds; (D) HT + 5% *M. oleifera* seeds; (E) HT + 10% *M. oleifera* seeds.

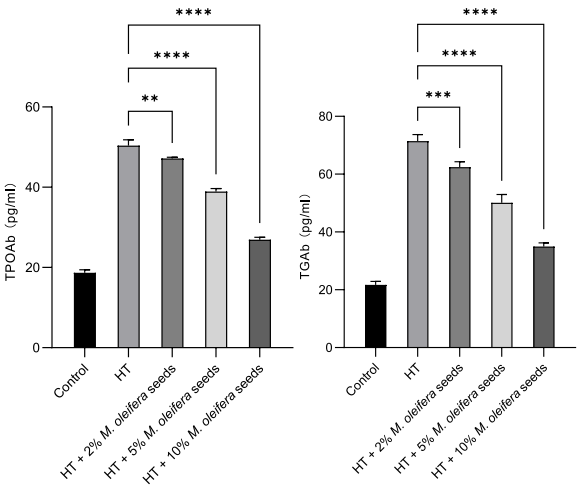

Fig. 2 Serum concentrations of TPOAb and TGAb measured by ELISA. Data are presented as mean ± SD. * $p < 0.05$, ** $p < 0.01$, *** $p < 0.001$, and **** $p < 0.0001$ versus the HT model group.

10% *M. oleifera* seed powder significantly inhibited transcription of pro-inflammatory cytokine genes and restored *Il10* mRNA expression (** $p < 0.01$, *** $p < 0.001$, **** $p < 0.0001$).

M. oleifera seeds inhibited T- and B-lymphocyte infiltration (CD3 and CD19) IHC

To further assess lymphocytic infiltration within thyroid tissues of HT mice, immunohistochemical staining was conducted using CD3 as a specific marker for T lymphocytes and CD19 for B lymphocytes. Representative IHC micrographs of CD3 and CD19 immunostaining are displayed in Fig. 5 and Fig. 6, respectively, with quantitative mean optical density (MOD) analyses illustrated in Fig. 7.

For CD3 staining (Fig. 7A), untreated HT mice exhibited markedly elevated CD3-positive MOD values. Intervention with graded doses of *M. oleifera* seeds decreased CD3 staining density in a dose-dependent fashion. Significant differences were observed between the HT group and the medium-dose *M. oleifera* seed group (** $p < 0.01$), as well as between the HT group and the high-dose seed group (*** $p < 0.001$).

Consistent with the CD3 results, CD19 MOD levels (Fig. 7B) were markedly elevated in HT mice. Medium-dose *M. oleifera* seed treatment significantly reduced CD19-positive staining density relative to the HT group (*** $p < 0.001$), and this inhibitory effect was more pronounced in the high-dose intervention group (**** $p < 0.0001$).

Collectively, these immunohistochemical data demonstrate that dietary *M. oleifera* seed supplementation alleviates autoimmune thyroid injury by suppressing excessive thyroid infiltration of $CD3^+$ T and $CD19^+$ B lymphocytes.

DISCUSSION

HT is one of the most common autoimmune diseases affecting the thyroid gland. In the present study, we employed the established thyroglobulin immunization approach to generate a mouse model of autoimmune Hashimoto's thyroiditis [1]. Significantly higher levels

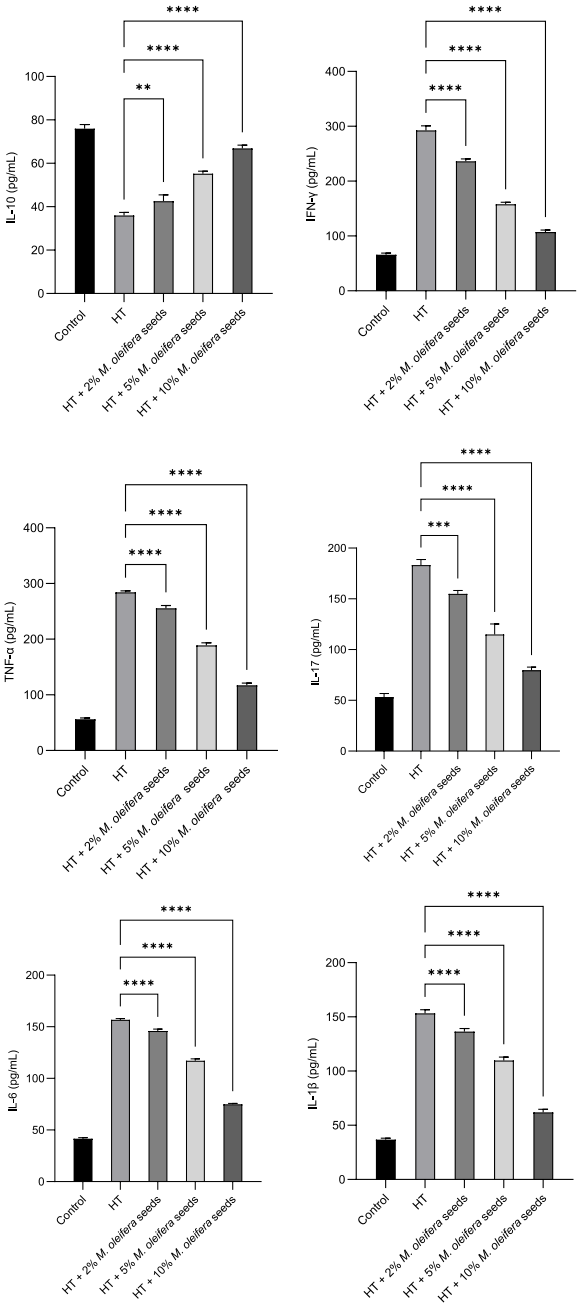

Fig. 3 Serum concentrations of inflammatory cytokines (IFN-γ, TNF-α, IL-17, IL-6, IL-1β, and IL-10) detected by ELISA. Data are presented as mean ± SD. * $p < 0.05$, ** $p < 0.01$, *** $p < 0.001$, **** $p < 0.0001$ versus the HT group.

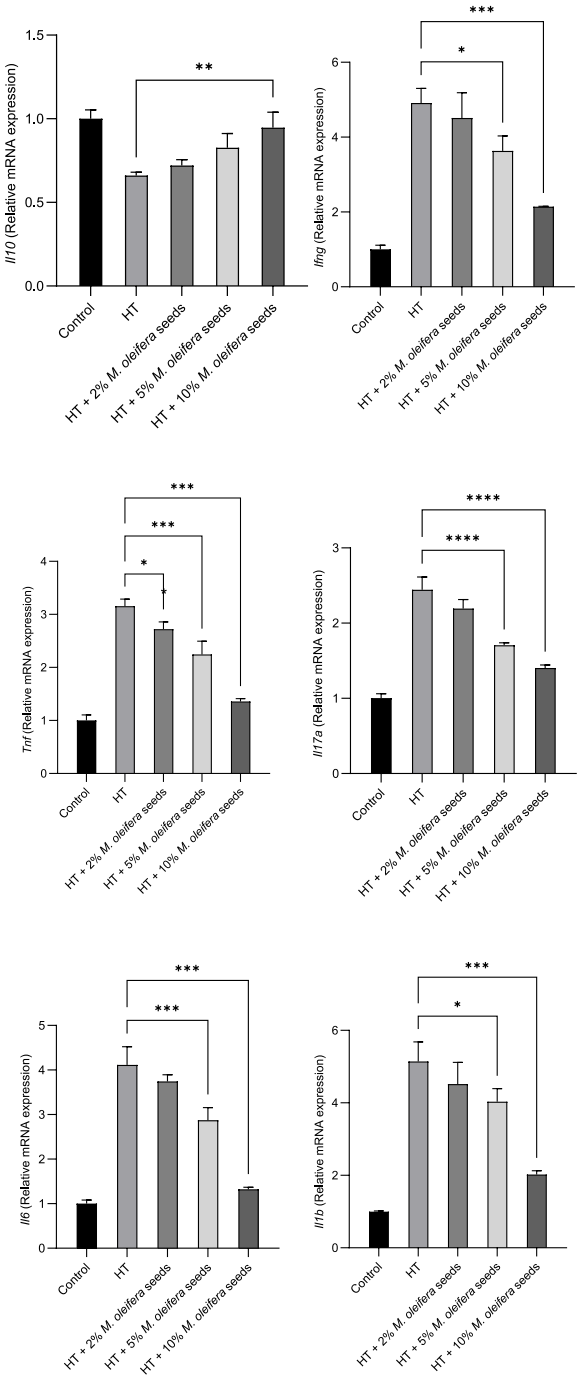

Fig. 4 Relative mRNA expression levels of *Ifng*, *Tnf*, *Il17a*, *Il6*, *Il1b*, and *Il10* in mouse thyroid tissues determined by RT-qPCR. Data are presented as mean ± SD. * $p < 0.05$, ** $p < 0.01$, *** $p < 0.001$, **** $p < 0.0001$ versus the HT model group.

of TPOAb and TGAb were detected in the experimental group than in the control group in this HT-induced hypothyroidism mouse model. During the development of HT, TPOAb and TGAb persistently increase. High antibody titers are usually maintained over time, and this reflects an increase in inflammation; thus, they are directly correlated with the extent of thyroid damage and may reflect disease progression in patients with Hashimoto's thyroiditis [19]. These findings confirm that a robust and reliable model has been established

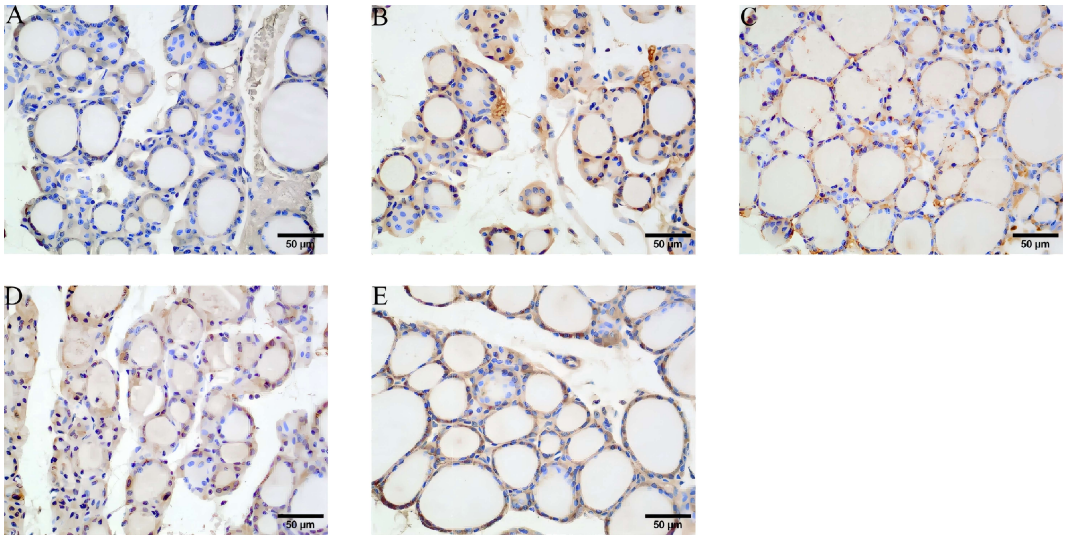

Fig. 5 Reduction of excessive T-lymphocyte infiltration in thyroid tissues of HT mice by *M. oleifera* seeds. Representative immunohistochemical micrographs of CD3 staining (a T lymphocyte marker) are shown. Scale bar = 50 µm. (A) Control group; (B) HT model group; (C) HT + 2% *M. oleifera* seeds; (D) HT + 5% *M. oleifera* seeds; (E) HT + 10% *M. oleifera* seeds.

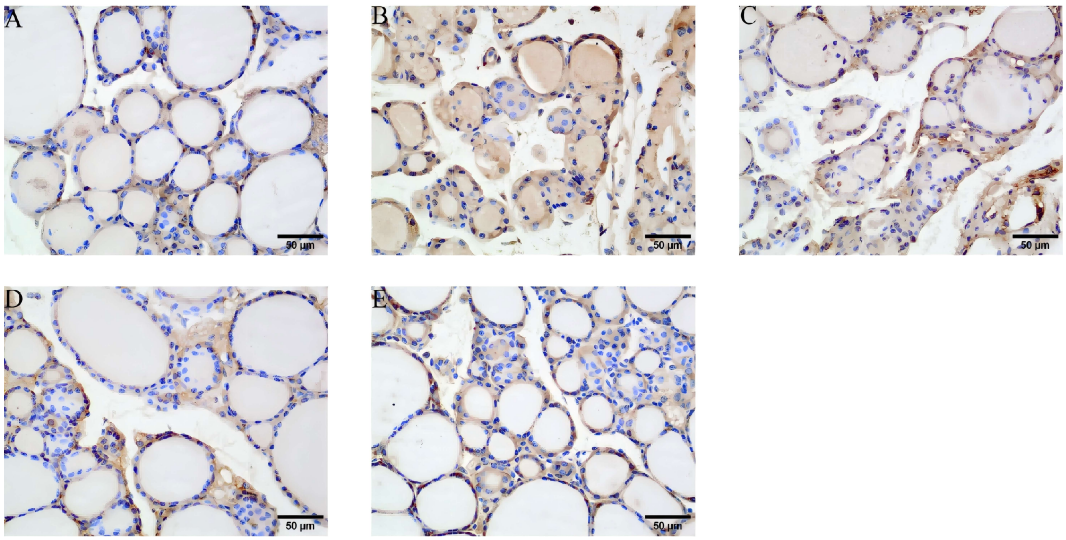

Fig. 6 Reduction of excessive B-lymphocyte infiltration in thyroid tissues of HT mice by *M. oleifera* seeds. Representative immunohistochemical micrographs of CD19 staining (a B lymphocyte marker) are shown. Scale bar = 50 µm. (A) Control group; (B) HT model group; (C) HT + 2% *M. oleifera* seeds; (D) HT + 5% *M. oleifera* seeds; (E) HT + 10% *M. oleifera* seeds.

and demonstrate autoimmune-mediated thyroid damage.

Moringa is an important plant predominantly found in tropical regions and is well known for its remarkable nutraceutical properties. Various parts of *Moringa*, including its leaves, flowers, and reproductive organs contain bioactive compounds such as proteins, vitamins, minerals, flavonoids, and isothiocyanates, which contribute to diverse health-promoting activities [20, 21]. Recently, numerous studies have focused on various parts of this species, with particular emphasis on its seeds due to their distinctive chemical composition and pharmacological properties. It is well established that *Moringa* seeds are rich sources of several bioactive compounds, including isothiocyanates, phenolic acids, and flavonoids. These compounds exhibit diverse pharmacological effects, such as antimicrobial, anticancer, antihyperglycemic, antioxidant, antihypertensive, anti-inflammatory, and cardioprotective activities [22, 23]. It has been reported that *M. oleifera* seeds can modulate the immune response and reduce psoriasis-like lesions in mice [24]. Isothiocyanates present in the seeds can reduce colitis severity, highlighting their therapeu-

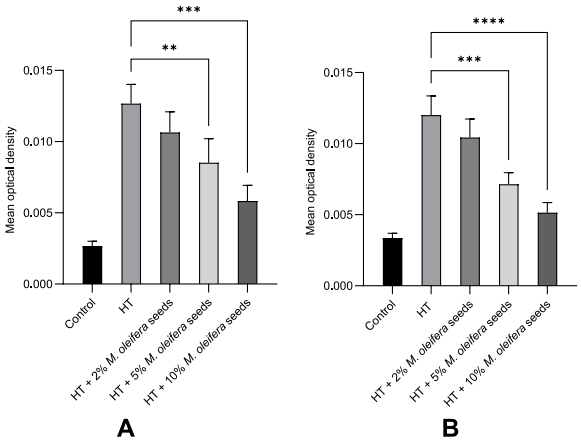

Fig. 7 Quantitative analysis of mean optical density (MOD) for CD3 and CD19 immunohistochemical staining in thyroid tissues. (A) Mean optical density of CD3-positive staining; (B) Mean optical density of CD19-positive staining. Data are presented as mean ± SD. * $p < 0.05$, ** $p < 0.01$, *** $p < 0.001$, **** $p < 0.0001$ versus the HT model group.

tic potential against immune-mediated diseases [5]. Specifically regarding Hashimoto's thyroiditis (HT)—an autoimmune disease—we report, for the first time, that treatment with *M. oleifera* seeds (2%, 5%, and 10% in the diet) significantly lowered serum titers of TPOAb and TGAb, suggesting that *M. oleifera* seeds inhibit autoantibody production associated with HT and thereby reduce thyroid tissue injury. In addition, HT mice exhibited marked morphological alterations in thyroid follicular structure and a significant increase in lymphocytic infiltration compared with controls. However, these pathological changes were attenuated by dietary supplementation with *M. oleifera* seeds at 2%, 5%, and 10%. Our findings suggest that *M. oleifera* seeds may have therapeutic potential for modulating autoimmune responses in HT.

Several plant-derived products, such as those used in traditional Chinese medicine (TCM), possess the ability to treat autoimmune diseases and inflammation by modulating cytokine levels [25]. Coix seed extract has also been reported to ameliorate rheumatoid arthritis by suppressing the synthesis of inflammatory mediators, such as TNF-α, IL-1β, and IL-6 [25]. Moreover, an *in vivo* study using rats with adjuvant-induced arthritis also demonstrated that Yangxue Jiedu Tang (YJT) exerts a significant therapeutic effect on rheumatoid arthritis symptoms [26]. The healing effect is achieved by reducing pro-inflammatory cytokine levels—including IL-1β, TNF-α, IL-6, IFN-γ, and IL-17—while simultaneously increasing IL-10 secretion. This finding further supports the potential of TCM to modulate immune function. Bioactive compounds present in *M. oleifera* seeds, such as isothiocyanates, have been reported to significantly inhibit pro-inflammatory signaling pathways. Notably, the most bioactive compound in *M. oleifera*—4-(α-L-rhamnopyranosyloxy)benzyl isothiocyanate—efficiently suppresses NF-κB-mediated inflammatory pathways [27]. This inhibition reduces the production of pro-inflammatory mediators, including TNF-α, IL-6, IL-1β, and nitric oxide, and significantly elevates IL-10 levels, thereby enhancing anti-inflammatory effects [12, 13]. In the present study, dietary supplementation with *M. oleifera* seeds at different doses reduced serum concentrations of IFN-γ, TNF-α, IL-17, IL-6, and IL-1β and decreased the mRNA expression levels of the corresponding genes (*Ifng*, *Tnf*, *Il17a*, *Il6*, and *Il1b*) in thyroid tissues. Moreover, the decreased IL-10 level was significantly restored. Treatment with *M. oleifera* seeds appears to exert its effects by reducing pro-inflammatory markers, including IFN-γ, TNF-α, IL-17, IL-6, and IL-1β, while enhancing IL-10 secretion. Simultaneous modulation of these opposing immune pathways suppressed excessive autoantibody production, resulting in significantly reduced serum levels of TPOAb and TGAb. These findings suggest that *M. oleifera* seeds may have immunomodulatory potential for the treatment of HT.

Consistent with the changes in inflammatory cytokines, our CD3 and CD19 immunohistochemical staining further revealed the cellular basis of thyroid inflammatory injury in HT mice. $CD3^+$ T lymphocytes and $CD19^+$ B lymphocytes extensively infiltrated the thyroid interstitium in untreated model mice—a classic pathological hallmark of Hashimoto's thyroiditis. Massively accumulated T cells secrete abundant Th1- and Th17-associated pro-inflammatory cytokines, such as IFN-γ and IL-17, while activated B cells drive excessive production of the thyroid autoantibodies TPOAb and TGAb within thyroid tissue [6, 7]. Intervention with *M. oleifera* seeds markedly reduced T and B lymphocyte infiltration in a dose-dependent manner, which may explain the synchronized reduction in pro-inflammatory cytokines and autoantibodies observed above [2, 8]. Collectively, these data indicate that *M. oleifera* seeds ameliorate thyroid autoimmunity primarily by suppressing excessive infiltration and activation of T and B lymphocytes.

This study has several limitations that should be acknowledged. The specific compounds present in *M. oleifera* seeds that are responsible for the observed effects have yet to be isolated and identified. Our findings demonstrate a potential immunomodulatory effect; however, the precise cell surface receptors involved, as well as their intracellular signal transduction pathways, remain to be elucidated by further biochemical studies. Furthermore, the translatability of these findings to clinical practice needs to be demonstrated by human studies.

CONCLUSION

In summary, this study provides novel evidence that *M. oleifera* seeds exhibit immunomodulatory and anti-

inflammatory effects in a thyroglobulin-induced HT mouse model. Treatment with *M. oleifera* seeds maintained follicular morphology, reduced lymphocytic infiltration, lowered serum levels of TPOAb and TGAb, and restored the balance between pro-inflammatory and anti-inflammatory cytokines.

Appendix A. Supplementary data

Supplementary data associated with this article can be found at https://dx.doi.org/10.2306/scienceasia1513-1874.2026.097.

REFERENCES

1. Zhang QY, Ye XP, Zhou Z, Zhu CF, Li R, Fang Y, Zhang RJ, Li L, et al (2022) Lymphocyte infiltration and thyrocyte destruction are driven by stromal and immune cell components in Hashimoto's thyroiditis. *Nat Commun* **13**, 775.
2. Ralli M, Angeletti D, Fiore M, D'Aguanno V, Lambiase A, Artico M, de Vincentiis M, Greco A (2020) Hashimoto's thyroiditis: An update on pathogenic mechanisms, diagnostic protocols, therapeutic strategies, and potential malignant transformation. *Autoimmun Rev* **19**, 102649.
3. Zaletel K, Gaberšček S (2011) Hashimoto's thyroiditis: From genes to the disease. *Curr Genomics* **12**, 576–588.
4. Ajjan RA, Weetman AP (2015) The pathogenesis of Hashimoto's thyroiditis: Further developments in our understanding. *Horm Metab Res* **47**, 702–710.
5. Kim Y, Wu AG, Jaja-Chimedza A, Graf BL, Waterman C, Verzi MP, Raskin I (2017) Isothiocyanate-enriched moringa seed extract alleviates ulcerative colitis symptoms in mice. *PLoS One* **12**, e0184709.
6. Wu F, Mao C, Mou X, Xu C, Zheng T, Bu L, Luo X, Lu Q, et al (2022) Decreased β-catenin expression contributes to IFNγ-induced chemokine secretion and lymphocyte infiltration in Hashimoto's thyroiditis. *Endocr Connect* **11**, e210451.
7. El-Zawawy HT, Farag HF, Tolba MM, Abdalsamea HA (2020) Improving Hashimoto's thyroiditis by eradicating Blastocystis hominis: Relation to IL-17. *Ther Adv Endocrinol Metab* **11**, 2042018820907013.
8. Yu S, Qi Y, Wang H, Jiang J, Sun L, Zhou Q (2017) Dysfunction of CD24+CD38+ B cells in patients with Hashimoto's thyroiditis is associated with a lack of interleukin 10. *Int J Biochem Cell Biol* **90**, 114–120.
9. Ali SA, Singh G, Datusalia AK (2021) Potential therapeutic applications of phytoconstituents as immunomodulators: Pre-clinical and clinical evidences. *Phytother Res* **35**, 3702–3731.
10. Swaroop AK, Lalitha CMVN, Shanmugam M, Subramanian G, Natarajan J, Selvaraj J (2022) Plant derived immunomodulators: A critical review. *Adv Pharm Bull* **12**, 712–729.
11. Dzuvor CKO, Pan S, Amanze C, Amuzu P, Asakiya C, Kubi F (2022) Bioactive components from *Moringa oleifera* seeds: Production, functionalities and applications — A critical review. *Crit Rev Biotechnol* **42**, 271–293.
12. Jaja-Chimedza A, Graf BL, Simmler C, Kim Y, Kuhn P, Pauli GF, Raskin I (2017) Biochemical characterization and anti-inflammatory properties of an isothiocyanate-enriched moringa (*Moringa oleifera*) seed extract. *PLoS One* **12**, e0182658.
13. Sailaja BS, Aita R, Maledatu S, Ribnicky D, Verzi MP, Raskin I (2021) Moringa isothiocyanate-1 regulates Nrf2 and NF-κB pathway in response to LPS-driven sepsis and inflammation. *PLoS One* **16**, e0248691.
14. Cai YJ, Wang F, Chen ZX, Li L, Fan H, Wu ZB, Ge JF, Hu W, et al (2018) Hashimoto's thyroiditis induces neuroinflammation and emotional alterations in euthyroid mice. *J Neuroinflammation* **15**, 299.
15. Wu Z, Cai Y, Xia Q, Liu T, Yang H, Wang F, Wang N, Yu Z, et al (2019) Hashimoto's thyroiditis impairs embryo implantation by compromising endometrial morphology and receptivity markers in euthyroid mice. *Reprod Biol Endocrinol* **17**, 94.
16. Wang N, Sun Y, Yang H, Xu Y, Cai Y, Liu T, Xia Q, Zhu D, et al (2021) Hashimoto's thyroiditis induces hippocampus-dependent cognitive alterations by impairing astrocytes in euthyroid mice. *Thyroid* **31**, 482–493.
17. Oyeleye SI, Ojo OR, Oboh G (2021) *Moringa oleifera* leaf and seed inclusive diets influenced the restoration of biochemicals associated with erectile dysfunction in the penile tissue of STZ-induced diabetic male rats treated with/without Acarbose drug. *J Food Biochem* **45**, e13323.
18. Li H, Min J, Mao X, Wang X, Yang Y, Chen Y (2018) Edaravone ameliorates experimental autoimmune thyroiditis in rats through HO-1-dependent STAT3/PI3K/Akt pathway. *Am J Transl Res* **10**, 2037–2046.
19. Koehler VF, Bojunga J (2021) Autoimmune thyroid disease. *Dtsch Med Wochenschr* **146**, 1329–1336.
20. Alegbeleye OO (2018) How functional is *Moringa oleifera*? A review of its nutritive, medicinal, and socioeconomic potential. *Food Nutr Bull* **39**, 149–170.
21. Arora S, Arora S (2021) Nutritional significance and therapeutic potential of *Moringa oleifera*: The wonder plant. *J Food Biochem* **45**, e13933.
22. Shahbaz M, Naeem H, Batool M, Imran M, Hussain M, Mujtaba A, Alsagaby SA, Al Abdulmonem W, et al (2024) Antioxidant, anticancer, and anti-inflammatory potential of *Moringa* seed and *Moringa* seed oil: A comprehensive approach. *Food Sci Nutr* **12**, 6157–6173.
23. Louisa M, Patintingan CGH, Wardhani BWK (2022) *Moringa oleifera* Lam. in cardiometabolic disorders: A systematic review of recent studies and possible mechanism of actions. *Front Pharmacol* **13**, 792794.
24. Ma N, Tang Q, Wu WT, Huang XA, Xu Q, Rong GL, Chen S, Song JP (2018) Three constituents of *Moringa oleifera* seeds regulate expression of Th17-relevant cytokines and ameliorate TPA-induced psoriasis-like skin lesions in mice. *Molecules* **23**, 3256.
25. Hu Y, Zhou Q, Liu T, Liu Z (2020) Coixol suppresses NF-κB, MAPK pathways and NLRP3 inflammasome activation in lipopolysaccharide-induced RAW 264.7 cells. *Molecules* **25**, 894.
26. Lv J, Wang Y, Xu J, Zhou T, Chen Z, Yang H, Di T, Li P (2022) Protective effect of Yangxue Jiedu Soup against psoriasis-like lesions by regulating TLR4/NF-κB signaling pathway mediated by secretion of exosome HSP70. *Biomed Pharmacother* **147**, 112604.
27. Malisorn N, Bootkotr W, Khamkhai T, Chaikan A, Seubsasana S (2023) Celastrol attenuates interleukin-8 release from LPS-activated human monocytes and monocyte-derived macrophages by inhibiting the NF-κB signalling pathway. *ScienceAsia* **49**, 653–660.

Appendix A. Supplementary data

Table S1 Primer sequences used for quantitative real time PCR in the present study.

Gene	Forward primer (5′ → 3′)	Reverse primer (5′ → 3′)	Product size (bp)
Il10	ACATACTGCTAACCGACTC	TCTTCAGCTTCTCACCC	165
Ifng	AGTGGCATAGATGTGGAA	CTCAAACTTGGCAATACTC	243
Tnf	ACAGAAAGCATGATCCGCGA	TTGCTACGACGTGGGCTAC	286
Il17a	CTACCTCAACCGTTCCAC	TCTCAGGCTCCCTCTTC	188
Il6	TAACAGATAAGCTGGAGTC	TAGGTTTGCCGAGTAGA	115
Il1b	TTCCCATTAGACAACTGC	GATTCTTTCCTTTGAGGC	198
Actb (β actin)	GCCAGAGCAGTAATCTCCTTCT	AGTGTGACGTTGACATCCGTA	112